

Loose Bodies in a Sublabral Recess

Diagnosis and Treatment

Kevin Kaplan, M.D., Deenesh T. Sahajpal, M.D., F.R.C.S.C., and Laith Jazrawi, M.D.

Abstract

A case of a 26-year-old male with symptoms resulting from loose bodies residing in a sublabral recess is presented. Operative intervention using the standard arthroscopic portals in addition to an accessory posterior portal was successful in removing the loose bodies and approximating the edges of the sublabral foramen. The shoulder is a complex region made up of numerous anatomic structures, which if damaged may be responsible for a patient's pathology. Normal anatomic variations also exist, which in certain situations, may contribute to a patient's presentation. One example of a normal anatomic variation is the sublabral foramen, which represents an unattached anterosuperior labrum.

A sublabral foramen is a congenitally unattached anterosuperior labrum, typically at the two o'clock position¹ found in 12% of individuals.² Reports in the literature demonstrate that the normal anatomic limit of the sublabral foramen is the anterior glenoid notch.³⁻⁷ Sublabral foramina provide an opening to the sublabral recess through which debris can migrate. Shoulder stability is typically not compromised by this congenital defect, but physicians should be cognizant that its presence should be included as part of the differential diagnosis of shoulder pathology.^{8,9}

Case

A 26-year-old male presented with right shoulder pain of several months duration. The patient had a history of a right shoulder dislocation seven years prior to this presentation

Kevin Kaplan, M.D., Deenesh T. Sahajpal, M.D., F.R.C.S.C., and Laith Jazrawi, M.D., are from the NYU-Hospital for Joint Diseases Department of Orthopaedic Surgery, New York, New York.

Correspondence: Kevin Kaplan, M.D., NYU-Hospital for Joint Diseases Department of Orthopaedic Surgery, 301 East 17th Street, New York, New York 10003.

and for which he had undergone closed reduction. Since that time, the patient had no complaints of pain, locking, catching, apprehension, or instability in the right shoulder.

Several months prior to the initial visit, the patient was playing basketball and began to feel some catching and locking in his right shoulder. The patient did not recall any specific traumatic event prior to the onset of pain. The patient had been taking naproxen prior to his initial visit with no relief of symptoms. The pain was occasional, sharp, and persistent in nature and was made worse with general activity and there were no alleviating factors.

Physical examination demonstrated no evidence of gross clicking or catching. However, the patient experienced pain with forward elevation of his arm and mildly positive impingement signs. Obrien's, crank, and biceps load tests were negative. The remainder of the physical exam was unremarkable.

Radiographs of the right shoulder demonstrated evidence of loose bodies (Fig. 1). The MRI demonstrated a questionable defect in the anterior articular hyaline cartilage of the glenoid at the mid portion with an intact glenoid labrum. Low signal intensity foci were seen within the joint fluid, which were consistent with loose bodies (Fig. 2).

Physical therapy in addition to anti-inflammatory medication was unsuccessful in treating this patient's acute pain and right shoulder arthroscopy was therefore indicated.

Examination under anesthesia demonstrated normal range of motion throughout his right upper extremity. The patient was placed in a lateral decubitus position with 15 pounds of balance suspension traction.

The standard posterior and anterior arthroscopic portals were created. Initial intra-articular inspection demonstrated a sublabral foramen with an additional glenoid articular cartilage defect at that level (Fig. 3).

Upon inspection of the sublabral foramen, six loose bodies were noted to reside in the sublabral recess (Fig.

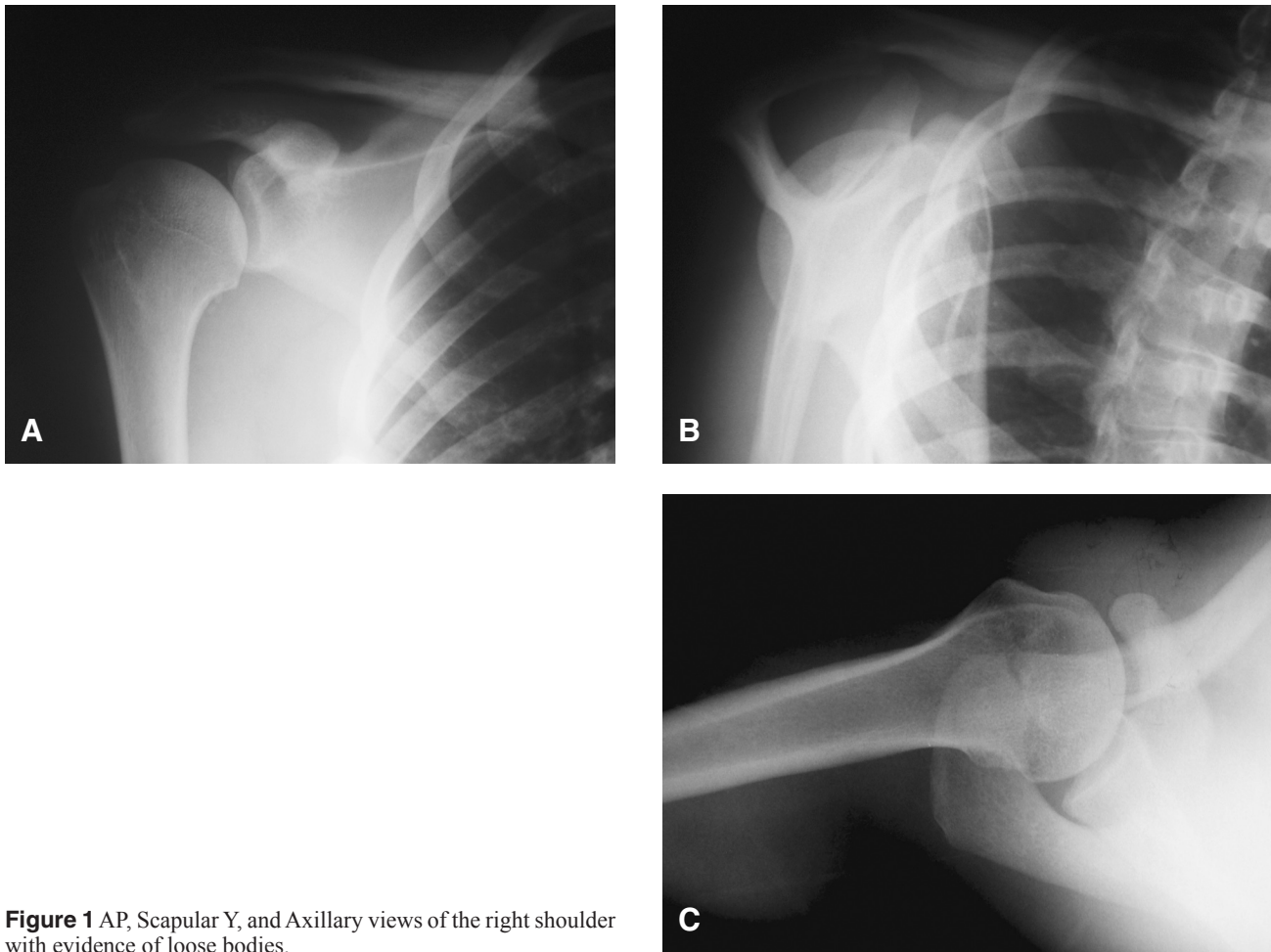


Figure 1 AP, Scapular Y, and Axillary views of the right shoulder with evidence of loose bodies.

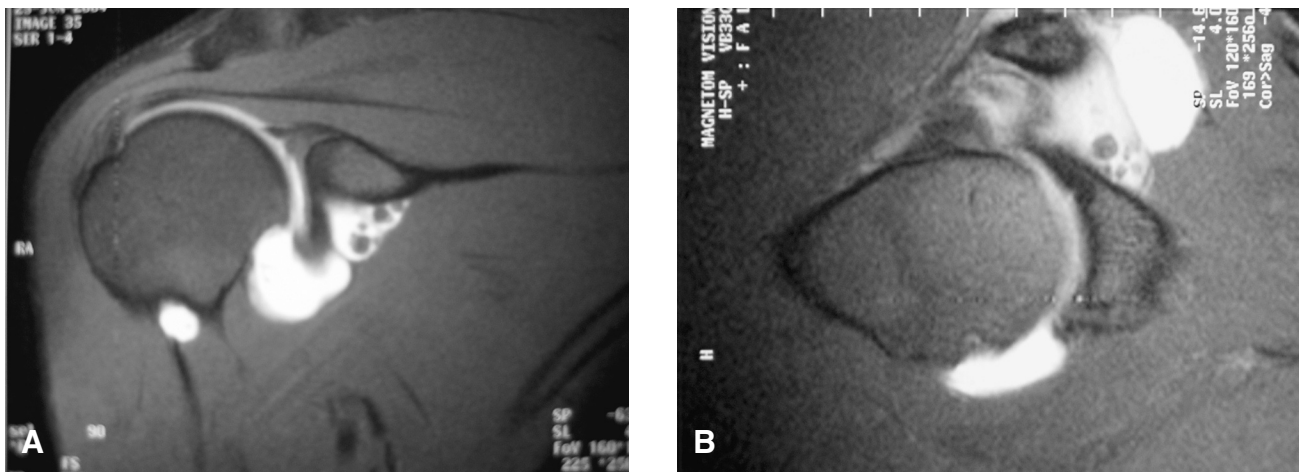


Figure 2 Magnetic resonance images demonstrating loose bodies in the sublabral recess.

3). Thus, two anterior working portals were created in the rotator interval to assist in their removal. In addition, an additional accessory posterior portal was created to assist in the removal of several loose bodies that were unable to be recovered with the anterior portals alone (Fig. 4). At this

point, the sublabral foramen was arthroscopically repaired with a 3.0 mm Biosuturetak (Arthrex, Naples, FL), which was inserted in standard fashion to prevent reaccumulation of additional loose bodies (Fig. 5).

The previously noted full cartilage defect at the three

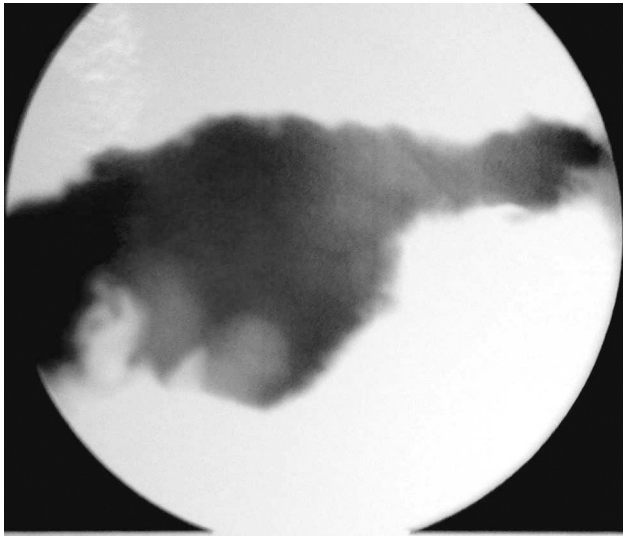

Figure 3 Sublabral foramen with loose bodies deep in the recess.

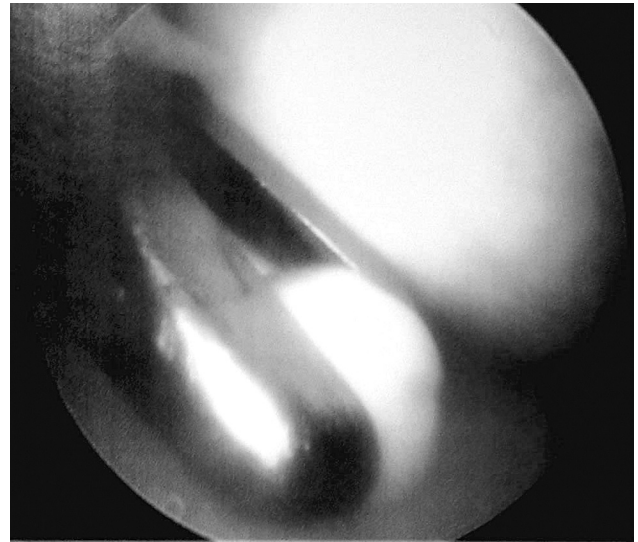


Figure 4 Retrieval of loose bodies.

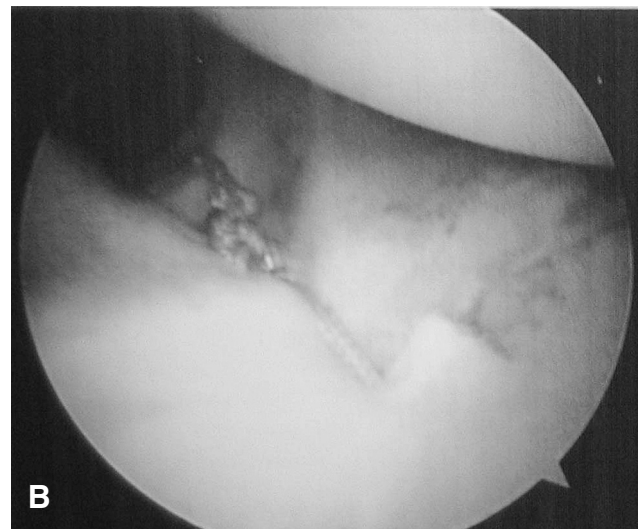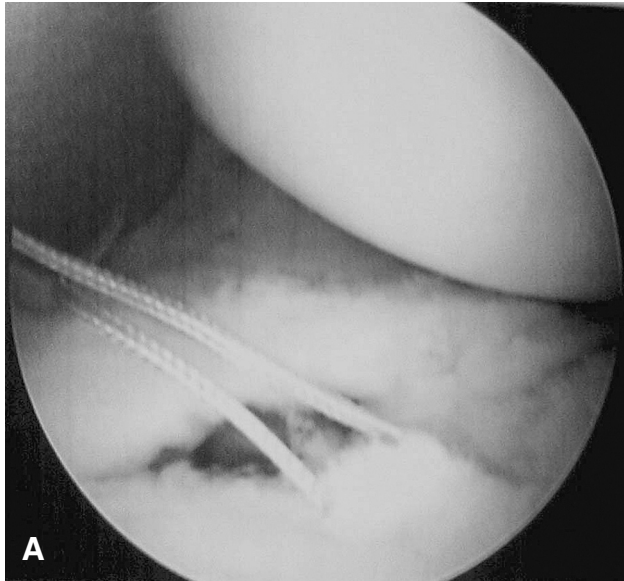


Figure 5 Repair of the sublabral foramen.

o'clock position was debrided of loose flaps to a bleeding bony bed to encourage new fibrocartilage formation. In addition, there was no evidence of a rotator cuff tear or SLAP tear. The arthroscopic instruments were then removed, and the portals were closed with #3-0 nylon sutures and a sterile dressing applied.

The specimens consisted of four tan to white loose bodies measuring in aggregate 2 x 0.5 x 0.3 cm (two additional loose bodies were lost to suction) (Fig. 6). Microscopic examination revealed the loose bodies to be composed of osteocartilaginous material.

The patient was placed in a physical therapy program and reported complete relief of his symptoms. At two years

follow up, the patient has a full painless range of motion and has returned to his previous level of activity.

Discussion

The glenoid labrum is composed of fibrocartilaginous tissue that serves to broaden the articular surface and increase load distribution in the shoulder joint.¹⁰ In addition, the glenohumeral ligaments and capsule attach to the fibrocartilaginous zone of the labrum. Superior, middle, and inferior glenohumeral ligaments contribute to the stability of the glenohumeral complex.

The anterior glenohumeral ligament complex consists of the superior glenohumeral ligament (SGHL), middle

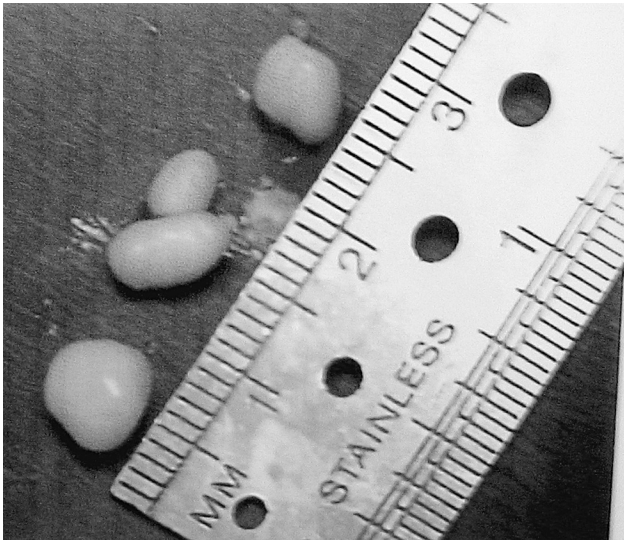

Figure 6 Loose bodies retrieved from the sublabral recess.

glenohumeral ligament (MGHL), the anterior band of the inferior glenohumeral ligament (AIGHL), and the anterior labrum. The superior glenoid tubercle is the attachment for the SGHL, while the middle and superior labrum is the attachment for the MGHL. Finally, the AIGHL attaches onto the anterior labrum.¹¹

The reports in the literature indicate that there are variations in the anatomy of the anterosuperior portion of the glenoid labrum.^{2,12} Five normal variations based on the shape of the labrum were discussed by Detrisac and Johnson.¹³ In addition, Cooper and associates described the variations in morphology between the superior and inferior portions of the glenoid.^{12,14} They describe a rounded inferior surface and a mobile, meniscoid superior labrum. One such variation is the presence of a sublabral foramen, which is found in 12% of individuals and is thought to be a congenital phenomenon.² Magnetic resonance studies have demonstrated that the unattached labrum associated with a sublabral foramen does not extend below the region of the anterior glenoid notch.^{3-7,15} In addition, the sublabral foramen lies anterior to the biceps-labral complex. This variation differs from a Buford complex, which is an absent anterosuperior labrum in combination with a cord-like middle glenohumeral ligament.

McNiesh and Callaghan utilized computed tomography arthrography to identify sublabral foramina. In their study, contrast dye materialized between the labrum and the glenoid.¹⁶ As stated previously, the sublabral foramen is considered a normal anatomic variant and the shoulder joint functions appropriately in the presence of such a defect given that the glenohumeral ligaments and rotator cuff muscles are intact.² Habermeyer and coworkers furthered this discussion by proving that the intraarticular pressure gradient, which can be considered a marker for an intact glenohumeral capsular structure, remained unaffected in patients with a

sublabral foramen.¹⁷ Furthermore, Schulz and colleagues demonstrated that an isolated sublabral foramen has no effect on anterior or inferior glenohumeral instability.⁹ However, Rao and associates demonstrated that anterosuperior labral variations could be associated with specific intraarticular abnormalities and findings on physical exam. Specifically, patients with these anatomic variations had an increased incidence of anterosuperior labral fraying, posterosuperior labral fraying, subscapularis tendon tears, and type-II SLAP lesions.¹⁴

Although much of the literature regarding sublabral foramen suggests that the stability of the shoulder is unaffected and that this defect should be treated non-operatively,^{8,9} a sublabral foramen can predispose a patient to pathology that can be prevented via surgical closure. However, it is important to recognize that repair of normal anatomic variants can also cause some increased pain and restricted range of motion. It was felt in this case that the sublabral foramen may have contributed to the patient's pathology and was closed to prevent potentially future loose body production or accumulation.

Retrieval of loose bodies in a sublabral recess is simplified by using an accessory posterior portal. The standard posterior portal is typically 2 cm inferior to and 1 cm medial to the acromion at its posterolateral edge.¹⁸ The anterior portal can then be placed under direct visualization. These portals do not allow adequate access to the inferior and posterior recesses of the glenohumeral joint without damaging the articular cartilage.¹⁹ DiFelice and associates, using cadaveric specimens, demonstrated that an accessory posterior portal is a safe and effective way to provide unlimited access to the glenohumeral joint. These investigators described this portal to be approximately 2 cm inferior to the standard posterior portal at the 8 o'clock or 4 o'clock position.²⁰ Davidson and Rivenbrugh also described an accessory posteroinferior portal at the 7 o'clock position for access to the inferior capsular recess.²¹ Both studies stress the importance of recognizing the proximity of the axillary nerve and its branch to the teres minor, which lies inferior to the glenohumeral joint capsule. A study by Bryan and coworkers demonstrated that the average distance of an accessory posterior portal from the axillary nerve is approximately 1.89cm (range: 0.5 to 4.0 cm).²² The posterior accessory portal in this case, as described by DiFelice and colleagues,²⁰ provided excellent visualization to the sublabral foramen and recess, which aided in the successful retrieval of loose bodies and repair of the sublabral foramen.

References

1. Mileski R, Snyder S: Superior labral lesions in the shoulder: pathoanatomy and surgical management. *J Am Acad Orthop Surg.* 1998;6(2):121-31.
2. Williams M, Snyder S, Buford D: The Buford Complex – The “cord-like” middle glenohumeral ligament and absent anterosuperior labrum complex: a normal anatomic variant.

- Arthroscopy. 1994;10(3):241-7.
3. Stoller D, Wolf E: *The Shoulder. Magnetic Resonance Imaging in Orthopedics and Sports Medicine* (2nd ed). Philadelphia: Lippincott-Raven, 1997.
 4. Kwak SM, Brown RR, Resnick D, Trudell D, Applegate GR, Haghighi P: Anatomy, anatomic variations, and pathology of the 11- to 3-o'clock position of the glenoid labrum: finding on MR arthrography and anatomic sections. *Am J Roentgenol* 1998;171:235-8.
 5. Beltran J, Bencardino J, Mellado J, Rosenberg Z, Irish RD: MR arthrography: variants and pitfalls. *Radiographics* 1997;17:1403-12.
 6. Yeh LR, Kwak SM, Kim YS: Anterior labroligamentous structures of the glenohumeral joint: correlation of MR arthrography and anatomic dissection in cadavers. *Am J Roentgenol* 1998;171:1229-36.
 7. Tuite M, Blankenbaker D, Seifert M, Ziegert A, Orwin J: Sublabral foramen and Buford Complex: inferior extent of the unattached or absent labrum in 50 patients. *Radiology* 2002;223:137-42.
 8. Andrews JR, Carson WG, McLeod WD: Glenoid labrum tears related to the long head of the biceps. *Am J Sports Med*. 1985;13:337-41.
 9. Schulz C, Hermann A, Pfahler M, Refior HJ, Mueller-Gerbl M: The sublabral foramen: does it affect stress distribution on the anterior glenoid? *J Shoulder Elbow Surg*. 2004;13(1):35-8.
 10. Soslowsky LJ, Flatow EL, Bigliani LU, Mow VC: Articular geometry of the glenohumeral joint. *Clin Orthop Relat Res* 1992;285:181-90.
 11. Ide J, Maeda S, Takagi K: Normal variations of the glenohumeral ligament complex: an anatomic study for arthroscopic Bankart repair. *Arthroscopy*. 2004;20(2):164-8.
 12. Cooper DE, Arnoczky SP, O'Brien SJ, Warren RF, DiCario E, Allen AA: Anatomy, histology, and vascularity of the glenoid labrum: an Anatomical study. *J Bone Joint Surg Am*. 1992;74:46-52.
 13. Detrissac DA, Johnson LL: *Arthroscopic Shoulder Anatomy: Pathologic And Surgical Implications*. Thorofare, NJ: Slack, 1986.
 14. Rao A, Kim TK, Chronopoulos E, McFarland E: Anatomical variants in the anterosuperior aspect of the glenoid labrum. *J Bone Joint Surg Am*. 2003;85:653-9.
 15. Palmer WE, Caslowitz PL, Chew FS: MR arthrography of the shoulder: normal intraarticular structures and common abnormalities. *Am J Roentgenol*. 1995;164:141-6.
 16. McNiesh LM, Callaghan JJ: CT arthrography of the shoulder: variations of the glenoid labrum. *Am J Roentgenol*. 1987;149:963-6.
 17. Habermeyer P, Schuller U, Wiedemann E: The intraarticular pressure of the shoulder: an experimental study on the role of the glenoid labrum in stabilizing the joint. *Arthroscopy*. 1992;8:166-72.
 18. Matthews LS, Fadale PD: Technique and instrumentation for shoulder arthroscopy. *Instr Course Lect*. 1989;38:169-76.
 19. Peterson CA, Altchek DW, Warren RF: Shoulder arthroscopy. In: Rockwood CA, Matsen FA (eds): *The Shoulder*. Philadelphia: WB Saunders, 1998, pp. 290-335.
 20. Difelice GS, William RJ, Cohen MS, Warren RF: The Accessory posterior portal for shoulder arthroscopy: description of technique and cadaveric study. *Arthroscopy*. 2001;17(8):888-91.
 21. Davidson PA, Rivenburgh DW: The 7-o'clock posteroinferior portal for shoulder arthroscopy. *Am J Sports Med*. 2002;30(5):693-6.
 22. Bryan WJ, Shauder K, Tullos HS: The axillary nerve and its relationship to common sports medicine shoulder procedures. *Am J Sports Med*. 1986;14:113-6.